

Clinical presentation and magnetic resonance imaging characteristics of lymphocytic hypophysitis: a systematic review with meta-analysis

Jia-Sheng Ju¹, Tao Cui², Jing Zhao², Jian-Liang Chen¹, Hai-Bing Ju²

¹Department of Neurosurgery, The Eighth Affiliated Hospital of Sun Yet-sen University, Shenzhen, China

²Department of Endocrinology, 920th Hospital of Joint Logistics Support Force of the Chinese People's Liberation Army, Kunming, China

Submitted: 20 April 2021; **Accepted:** 7 December 2021

Online publication: 14 December 2021

Arch Med Sci 2023; 19 (4): 976–986

DOI: <https://doi.org/10.5114/aoms/144628>

Copyright © 2021 Termedia & Banach

Corresponding authors:

Hai-Bing Ju MD

Department of Endocrinology
920th Hospital of Joint
Logistics Support Force
of the Chinese People's
Liberation Army
212 Dagan St
Xishan District
Kunming, 650032, China
Phone: +86 13187865520
Fax: +86 13187865520
E-mail: juhaibimg@163.com

Jian-Liang Chen MD

Department of Neurosurgery
The Eighth Affiliated Hospital
of Sun Yet-sen University
3025 Shennanzhong St
Futian District
Shenzhen 518000, China
Phone: +86 13902974061
Fax: +86 13902974061
E-mail: chemjl@126.com

Abstract

Introduction: This meta-analysis was performed to analyze the clinical presentation, magnetic resonance imaging (MRI) characteristics, and the management of lymphocytic hypophysitis (LYH).

Material and methods: Four different databases were searched from January 2010 to December 2020, two researchers independently conducted literature screening, data extraction, and quality evaluation. We used a random effects meta-analysis to calculate summary relative risks with 95% CI.

Results: This meta-analysis showed that the percentage of women among LYH patients was 78%. LYH was associated with pregnancy in 15% of female patients, with headache (49%) and symptoms of central diabetes insipidus (CDI) (45%) being the most frequent presentation. In 24% of LYH patients, there was an association with another autoimmune disease. The incidence of secondary hypogonadism, secondary hypoadrenalism, secondary hypothyroidism, and growth hormone deficit was 54%, 49%, 43%, and 22%, respectively. Pituitary contrast enhancement (63%), symmetrical pituitary enlargement (60%), thickening of the pituitary stalk (58%), sella mass or suprasellar extension (58%), and loss of posterior pituitary hyperintensity (50%) were typical MRI findings. Regarding LYH treatment, the percentage of patients who had observation or hormone replacement, steroid therapy, and surgery was 43%, 36%, and 34%, respectively.

Conclusions: It is of great significance to fully understand the clinical characteristics of lymphocytic hypophysitis, reduce missed diagnosis and misdiagnosis, avoid unnecessary surgery and maintain normal pituitary function.

Key words: lymphocytic hypophysitis, clinical characteristics, magnetic resonance imaging, management, pituitary function.

Introduction

Lymphocytic hypophysitis (LYH) is a rare disease of presumed autoimmune etiology characterized by lymphocytic infiltration of the pituitary gland followed by fibrosis [1]. The presenting symptoms correspond to the location of the lesion. The most common presenting symptoms in female patients are amenorrhea and failure to lactate secondary to hypopituitarism, as the inflammatory process damages both the anterior

and posterior pituitary gland, along with the pituitary stalk. There may also be neurological symptoms such as headaches and visual field defects secondary to the rapid expansion of the infiltrated pituitary gland. LYH has an estimated annual incidence of approximately 0.1 cases per million population, based on extrapolated data sourced from the UK, where 0.8% of consecutive pituitary operations were found to demonstrate LYH histologically [2]. However, its true incidence in the general population may be underestimated.

Due to its rarity, clinical data to guide the diagnosis and treatment of LYH have been limited, and there are no specific guidelines on management. Gutenberg noted that approximately 40% of patients with LYH were diagnosed as pituitary macroadenomas on the basis of radiology and underwent unnecessary surgery [3]. Many of the landmark articles on LYH to date have only included those patients undergoing surgery with a confirmed histological diagnosis. However, as LYH is an autoimmune disease, most patients do not need surgical treatment [4]. Therefore, it is of great practical significance to fully understand the clinical characteristics of LYH and to improve the diagnostic rate without the need for pathological evidence.

The aim of this meta-analysis was to analyze the clinical presentation, endocrine status, magnetic resonance imaging (MRI) characteristics, and management of LYH, in order to improve clinician awareness of LYH and the prognosis and quality of life of patients with the disease, and to reduce healthcare costs.

Material and methods

This meta-analysis was conducted using the Preferred Reporting Items for Systematic Reviews and Meta-Analyses (PRISM) guidelines. Author's statement: all supporting data are included in the article and its supplementary materials. This study did not require ethical approval because all analyses were based on previously published studies.

Literature retrieval and screening, data extraction and quality evaluation

Two researchers searched the Cochrane Controlled Trials Register (CCTR), Ovid, PubMed, Excerpta Medica Database (EMBASE), and the Chinese Biomedical Literature Databases (CBM). The databases were searched from January 2010 to December 2020. References and related reviews found in the literature were also retrieved. Primary search terms were hypophysitis, primary hypophysitis, autoimmune hypophysitis, lymphocytic hypophysitis, clinical features, clinical characteristic, clinical presentation, clinical manifestations, MRI, management, and treatment.

Two researchers independently conducted literature screening, data extraction, and quality evaluation. Results were cross-checked and any disagreements were mediated by discussion or with the assistance of a third-party researcher. All literature was screened sequentially for inclusion and exclusion criteria.

Inclusion and exclusion criteria

Inclusion criteria: All clinical studies that report the clinical characteristics of patients with LYH. The diagnostic criteria for LYH are based on pathological and clinical findings. The criteria for judging the endocrine function of each pituitary target gland conform to the diagnostic criteria in currently recognized authoritative international guidelines. These studies report at least any clinical feature of LYH, including gender, clinical manifestations, pituitary function changes, MRI manifestations, other concomitant autoimmune diseases, or treatment. The evaluation of pituitary function depends on the detection of pituitary target gland hormones and the pituitary function test as follows:

Growth hormone (GH): GH secretion function was evaluated by the insulin hypoglycemic stimulation test and clonidine test, and GH peak < 5 ng/ml and/or IGF-1 decrease was judged as GH deficiency.

Pituitary-thyroid axis: Free triiodothyronine (FT3), total triiodothyronine (TT3), free thyroxine (FT4), total thyroxine (TT4), and thyroid stimulating hormone (TSH) were assessed for thyroid function.

Pituitary-adrenal axis: Assessment was made by measuring 24-hour urine free cortisol (24hUFC), serum cortisol and ACTH rhythm (8 am, 4 pm, 0 am), and performing the insulin hypoglycemic stimulation test. In the insulin hypoglycemic stimulation test, peak cortisol < 18 µg/dl was judged as adrenal hypoglycemic dysfunction.

Pituitary-gonadal axis: Assessment was made by measuring luteinizing hormone, follicle stimulating hormone, prolactin, estradiol, progesterone, testosterone levels, and performing the gonadotropin-releasing hormone (GnRH) excitation test. Hypogonadotropism was determined by the GnRH stimulation test when luteinizing hormone (LH) increased by less than 3–6 times or follicle stimulating hormone (FSH) increased by less than 50%.

Posterior pituitary function was assessed by measuring urine specific gravity and urine osmotic pressure after the vasopressin test.

Exclusion criteria: Case reports, abstracts, letters, animal experiments, conference literature, duplicate publications, and literature with incomplete original data where it is not possible to extract data.

Statistical analysis

Meta-analysis was performed using Stata 15 software. The combined rate of event incidence was used as the pooled effect size. All effect sizes were expressed as a 95% confidence interval (CI). A χ^2 test was used to test the heterogeneity of all included study literature. The significance level was set as $p = 0.10$. When $p > 0.10$ and $I^2 < 50\%$, the study results were not heterogenous and a fixed effects model was used for combined analysis. When $p < 0.10$ and $I^2 > 50\%$, the study results were heterogenous and a random effects model was used for combined analysis.

Results

Literature retrieval results

Preliminary inspection identified 326 study articles. After reading the title, abstract, and full text, those studies that did not meet the inclusion criteria were excluded. The final analysis group included 17 clinical studies with a total of 364 subjects with LYH [5–21]. The basic characteristics of the study included in this analysis are shown in Table I, and the baseline data are shown in Table II.

Patient features

Sixteen studies [6–21], involving a total of 355 patients, reported the ratio of males to females.

Heterogeneity analysis revealed no statistical heterogeneity among these 16 studies; thus, the fixed effects model was used for combined analysis. The results showed that the percentage of women among LYH patients was 78% (95% CI: 0.73–0.82) (Figure 1).

Thirteen studies [5–10, 15–21], involving a total of 241 patients, reported that LYH onset in female patients is related to pregnancy. Fifteen studies [5, 7–12, 14–21], involving a total of 340 patients, reported an association between LYH and other autoimmune diseases. In both study series, heterogeneity analysis revealed that there was statistical heterogeneity; thus, the random effects model was used for combined analysis. The results showed that in 15% of females, LYH was related to pregnancy (95% CI: 0.08–0.23) (Figure 2). The incidence of LYH patients with other autoimmune diseases was 0.24 (95% CI: 0.15–0.32), with Hashimoto’s thyroiditis being the most common coexisting autoimmune disease.

Sella mass-effect symptoms

All 17 studies [5–21], involving a total of 364 patients, reported headache as a symptom caused by LYH. Fifteen studies [6–13, 15–21], involving a total of 350 patients, reported visual field loss and visual impairment caused by LYH. In both study series, heterogeneity analysis revealed that

Table I. Basic information of published literature

Study ID	Journal	Publication year	Publication level	Research design and methodology	Dates when cases collected
An 2013	Chinese Journal of Chronic Disease Prevention and Control	2013	Full text	Retrospective study	2008–2011
Liu 2013	Chinese Journal of General Practitioners	2013	Full text	Retrospective study	2010–2011
Feng 2019	Chinese Journals of Practical Medicine	2019	Full text	Retrospective study	2013–2018
Wei 2018	Chinese Medical Journal	2018	Full text	Retrospective study	2001–2017
Xu 2020	Journal of Stereotactic and Functional Neurosurgery	2020	Full text	Retrospective study	2010–2019
Tirosh 2016	Endocr Pract	2016	Full text	Retrospective study	2008–2014
Zhu 2019	World Neurosurg	2019	Full text	Retrospective study	2011–2018
Kyriacou 2017	Pituitary	2017	Full text	Multicenter cohort study	2008–2011
Wang 2017	Clin Endocrinol	2017	Full text	Retrospective study	1999–2016
Iuliano 2011	Expert Rev Endocrinol Metab	2011	Full text	Retrospective study	2008–2011
Honegger 2015	J Clin Endocrinol Metab	2015	Full text	Retrospective study	2000–2013
Chiloiro 2017	Neuroendocrinology	2017	Full text	Retrospective study	2011–2015
Khare 2015	Pituitary	2015	Full text	Retrospective study	2006–2012
Park 2014	Endocrinol Metab	2014	Full text	Retrospective study	2001–2013
Atkins 2020	Endocrine Research	2020	Full text	Retrospective study	2000–2017
Amereller 2020	Exp Clin Endocrinol Diabetes	2020	Full text	Retrospective study	1997–2016
Hanife 2020	Endocrine Care	2020	Full text	Retrospective study	1999–2017

Table II. Baseline data of included studies

Study ID	Nationality	Number of patients (men/women)	Average age [years]	Course of disease
An 2013	Chinese	4/11	Median 46	Median 6 months
Liu 2013	Chinese	1/4	19–61	2–24 months
Feng 2019	Chinese	7/25	Median 31	Median 6 months
Wei 2018	Chinese	5/13	Mean 36.3	Median 3.5 months
Xu 2020	Chinese	3/1	Mean 46	Mean 2 months
Tirosh 2016	Israeli	0/9	Mean 33.7	Unclear
Zhu 2019	Chinese	4/16	Median 37	Mean 5 months
Kyriacou 2017	British	3/19	Median 37.5	Median 3 months
Wang 2017	Chinese	17/33	Mean 37.2	Median 4 months
Iuliano 2011	American	3/4	Mean 44	Unclear
Honegger 2015	German	5/19	Mean 40.7	Unclear
Chiloiro 2017	Italian	4/17	Mean 40	Unclear
Khare 2015	Indian	3/21	Median 31.5	Median 10 weeks
Park 2014	Korean	5/17	Mean 48	Unclear
Atkins 2020	Canadian	1/10	Mean 38	Mean 12 weeks
Amereller 2020	German	16/44	Mean 45	Unclear
Hanife 2020	Turkish	5/15	Median 41.5	Median 18 months

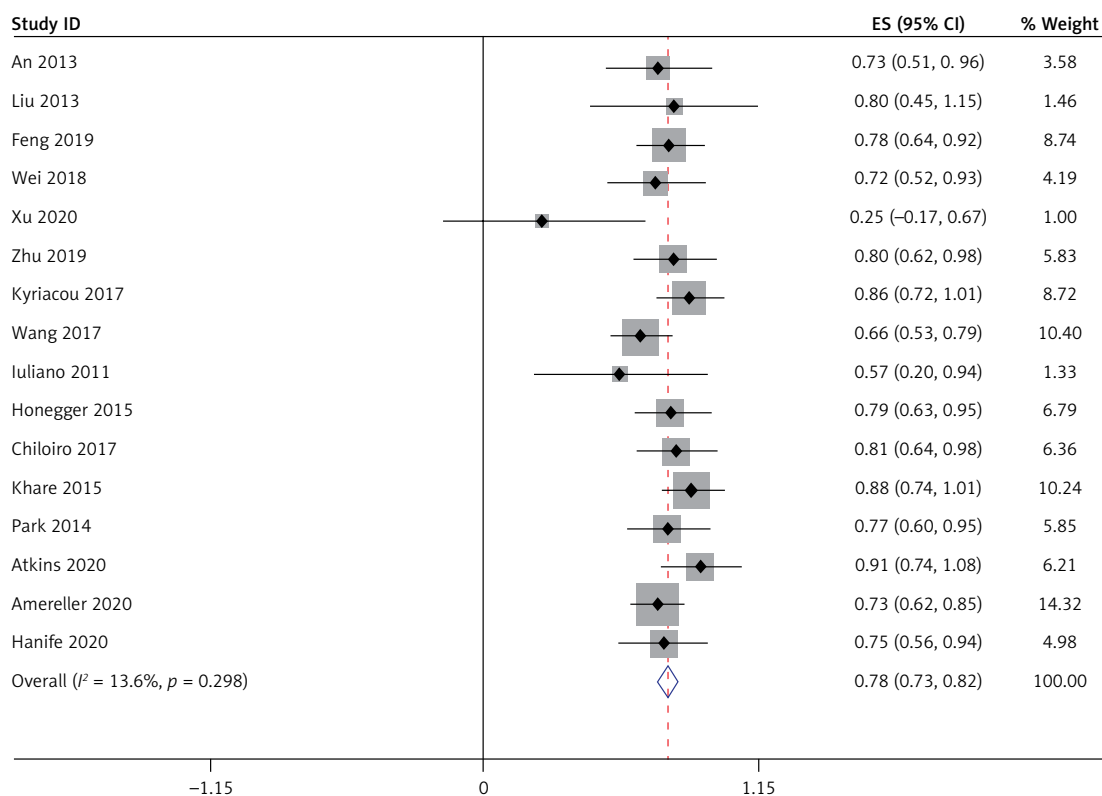


Figure 1. Female proportion

there was statistical heterogeneity; thus, the random effects model was used for combined analysis. The results showed that the incidence of headache was 0.49 (95% CI: 0.40–0.58) (Figure 3). The incidence of visual field loss and visual impairment was 0.26 (95% CI: 0.19–0.33).

Evaluation of pituitary function

Evaluation of anterior pituitary target gland function

All 17 studies [5–21], involving a total of 364 patients, reported the occurrence of hypoadrenalism,

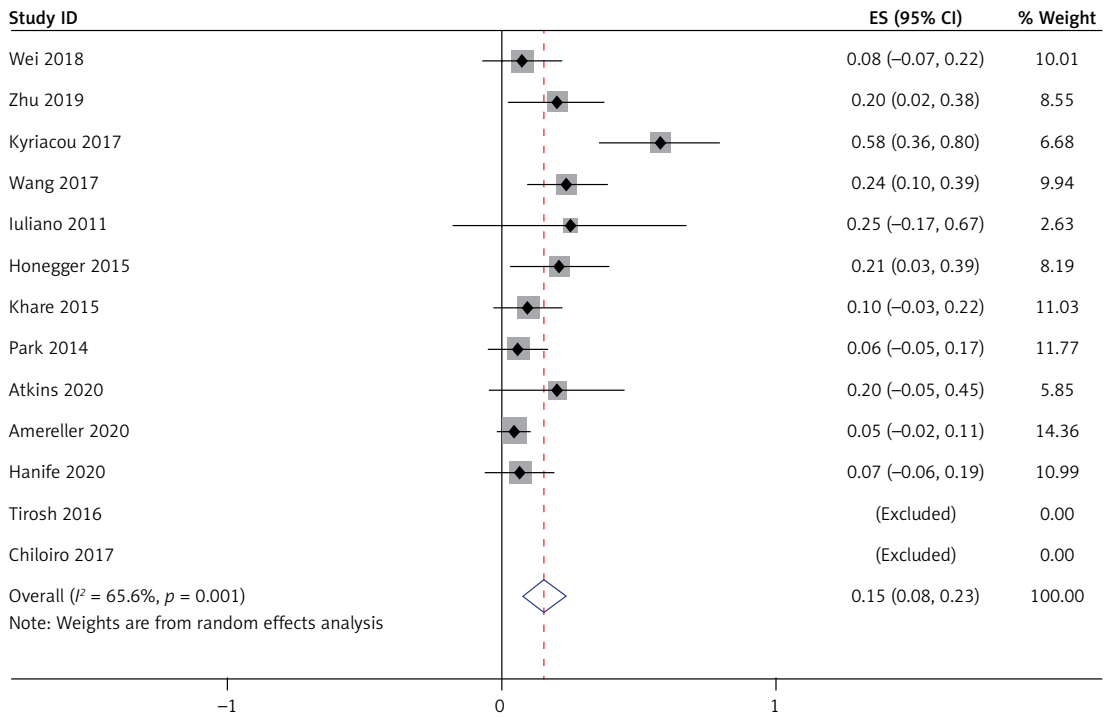


Figure 2. Proportion associated with pregnancy

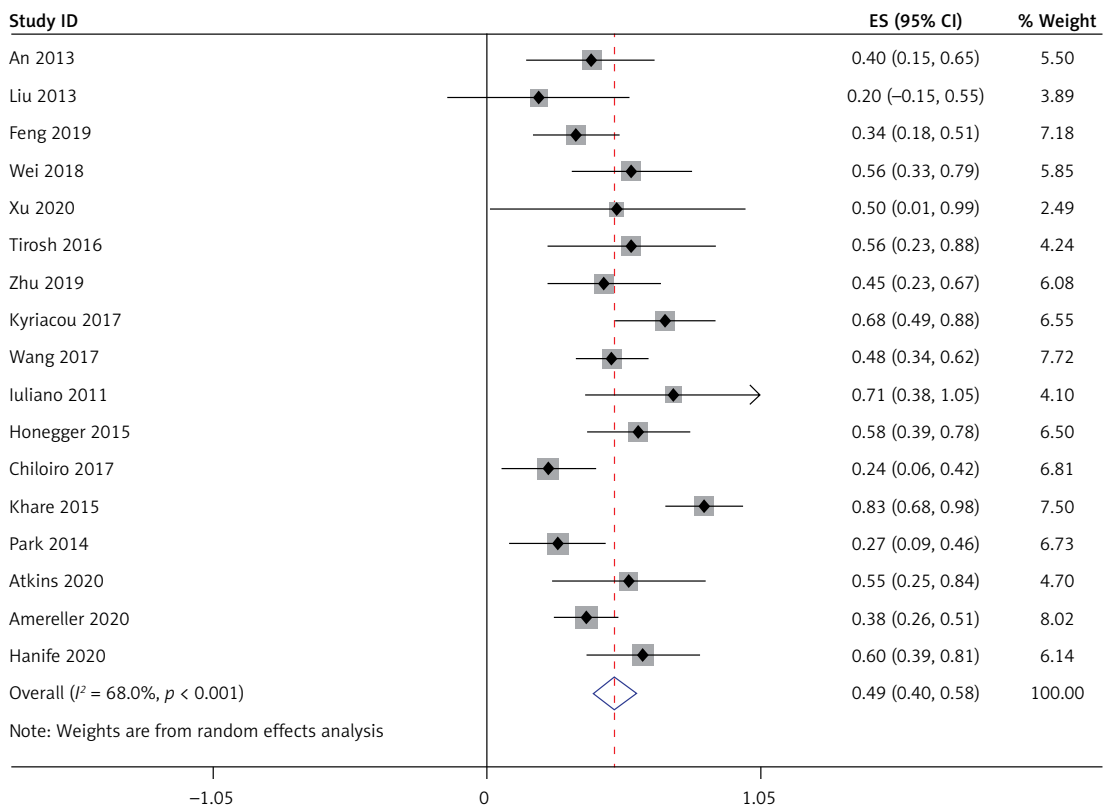


Figure 3. Proportion of headache

hypothyroidism, and hypogonadism in LYH patients. Heterogeneity analysis revealed that there was statistical heterogeneity among these 17 studies; thus, the random effects model was used for combined analysis. The results showed that the

incidence of secondary hypoadrenalism in LYH patients was 0.49 (95% CI: 0.38–0.60) (Figure 4). The incidence of secondary hypothyroidism was 0.43 (95% CI: 0.35–0.50), and the incidence of secondary hypogonadism was 0.54 (95% CI: 0.42–0.65).

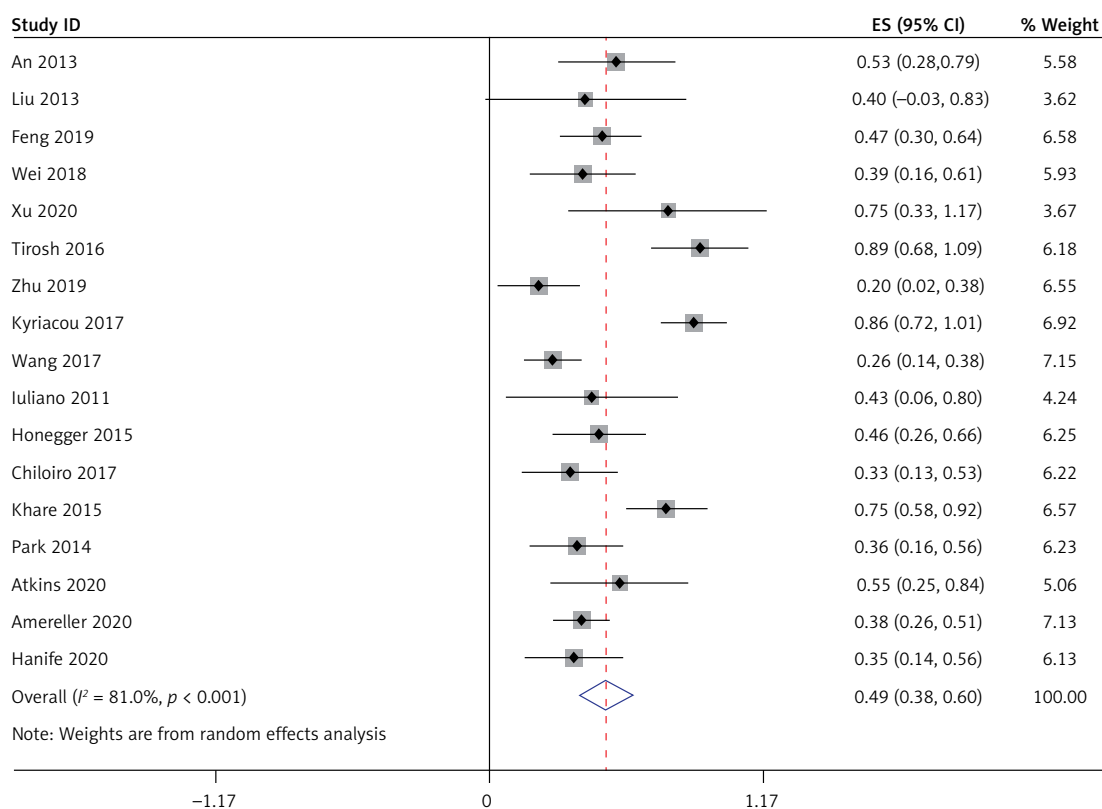


Figure 4. Incidence of secondary hypoadrenalism

Changes in growth hormone and prolactin levels

Thirteen studies [5–8, 10–11, 15–21], involving a total of 333 patients, reported the occurrence of low growth hormone levels in LYH patients. Sixteen studies [5–12, 14–21], involving a total of 360 patients, reported the occurrence of hyperprolactinemia in LYH patients. In both study series, heterogeneity analysis revealed that there was statistical heterogeneity; thus, the random effects model was used for combined analysis. The results showed that the incidence of growth hormone deficit in LYH patients was 0.22 (95% CI: 0.13–0.32) and the incidence of hyperprolactinemia in LYH patients was 0.29 (95% CI: 0.19–0.39) (Figure 5). Three studies [5, 7, 17] reported low prolactin levels in some patients with an incidence rate of 0.18 (95% CI: 0.08–0.28).

Central diabetes insipidus

All 17 studies [5–21], involving a total of 364 patients, reported the occurrence of central diabetes insipidus (CDI) in LYH patients. Heterogeneity analysis revealed that there was statistical heterogeneity among these 17 studies; thus, the random effects model was used for combined analysis. The results showed that the incidence of CDI in LYH patients was 0.45 (95% CI: 0.36–0.55) (Figure 6).

Magnetic resonance imaging findings

Ten different MRI characteristics of LYH were reported in 16 studies [5–10, 12–21], and each of these MRI characteristics was reported in between 2 and 13 of the 16 studies. The results showed that the commonest MRI characteristics of LYH were pituitary contrast enhancement (63%), symmetric pituitary enlargement (60%), thickening of the pituitary stalk (58%), sella mass or suprasellar extension (58%), loss of posterior pituitary hyperintensity (50%), chiasmal compression (38%), central pituitary necrosis (24%), cystic appearance (17%), cavernous sinus compression (17%), and dural tail sign (9%). The incidence of different MRI findings is shown in Table III.

Treatment

Treatment with glucocorticoids and surgery

All 17 studies [5–21] reported glucocorticoids and surgery in the treatment of LYH patients. Heterogeneity analysis revealed that there was statistical heterogeneity among these 17 studies; thus, the random effects model was used for combined analysis. The results showed that 36% (95% CI: 0.20–0.52) of LYH patients were treated with steroids, which was mainly glucocorticoid pulse therapy, with 34% (95% CI: 0.23–0.45) of LYH patients being treated surgically (Figure 7).

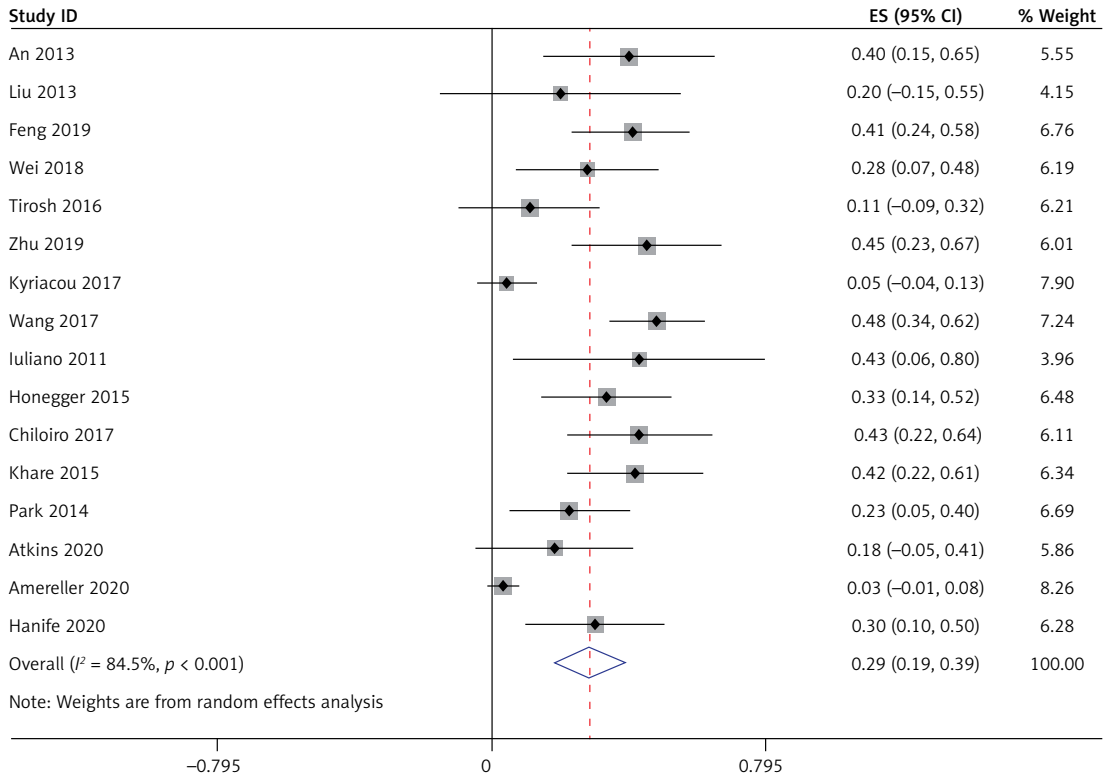


Figure 5. Incidence of hyperprolactinemia

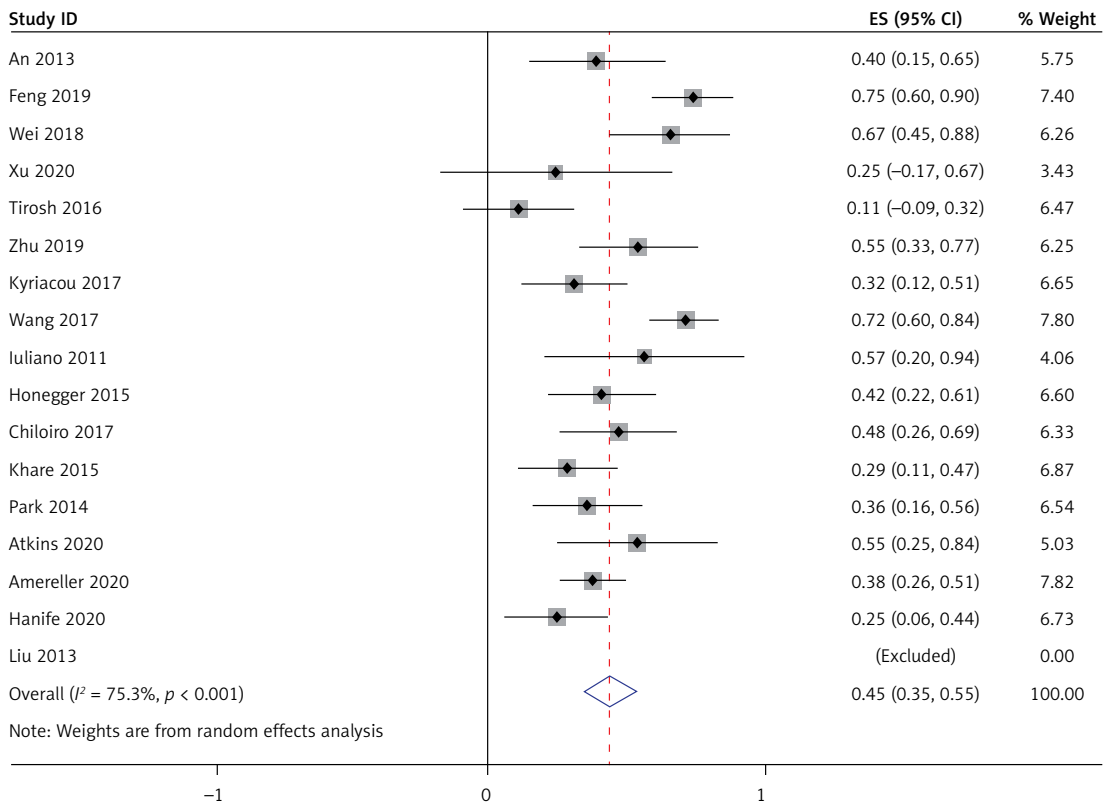


Figure 6. Incidence of central diabetes insipidus

Clinical follow-up observation or hormone replacement therapy

Nine studies [5, 8, 9, 11, 15, 17–20], involving a total of 239 patients, reported LYH patients receiving clinical follow-up observation or hormone replacement therapy. Heterogeneity analysis revealed that there was statistical heterogeneity among the nine studies; thus, the random effects model was used for combined analysis. The results showed that 43% (95% CI: 0.22–0.64) of LYH patients received clinical follow-up observation or hormone replacement therapy.

Discussion

Hypophysitis is a rare autoimmune disease characterized by inflammation and cell infiltration of the pituitary gland. It can be divided into primary and secondary hypophysitis, with LYH being the most common type of primary hypophysitis. In the last 10 years, an increasing number of clinical studies and case series have been published. The clinical manifestations of LYH are related to the severity of inflammation and the mass effect of the lesion, giving rise to four symptom categories: (1) symptoms resulting from sellar mass compression, such as headache, nausea, vomiting, and visual field impairment. Our analysis showed that the incidence of headache was 49% in 364 LYH patients and the incidence of visual field loss and visual impairment was 26% in 350 LYH patients, (2) symptoms of anterior pituitary hormone deficiency, where clinical presentation will vary depending on the hormone or hormones involved. Secondary hypoadrenalism can be manifest as weakness, fatigue, loss of appetite, nausea, vomiting, hypotension, and hypoglycemia. Secondary hypothyroidism can result in dry skin, cold intolerance, pallor, and reduced reaction times. Secondary hypogonadism can present with amenorrhea and loss of sexual desire. Our analysis showed that in 364 LYH patients, the incidence of secondary hypogonadism, secondary hypoadrenalism, secondary hypothyroidism, and growth hormone deficit was 54%, 49%, 43%, and 22%, respectively, (3) posterior pituitary involvement leads to partial or total CDI, manifest as polyuria and polydipsia. In our analysis, CDI occurred in 45% of 364 LYH patients, and (4) when the lesion involves the pituitary stalk, CDI, amenorrhea, galactorrhea, and other symptoms appear. In our analysis, hyperprolactinemia and low prolactin levels occurred in 45% and 18% of patients, respectively. LYH is common in women in late pregnancy and the early postpartum period: a case series reported prevalence of female gender among affected patients of between 52% and 71% [22]. An association with pregnancy was found in 5% [23]. Our analy-

Table III. Findings on magnetic resonance imaging

Data	Symmetric enlargement	Thickened pituitary stalk	Contrast enhancement	Sella mass or suprasellar extension	Loss of posterior pituitary hyperintensity	Cystic appearance	Chiasmal compression	Cavernous sinus compression	Central pituitary necrosis	Dural tail sign
Number of literature reports involved	13	13	10	12	9	6	6	3	2	2
Events	176	197	144	178	84	28	52	5	12	7
Total number of cases	290	296	206	282	150	144	136	29	48	74
Combined incidence	0.6	0.58	0.63	0.58	0.5	0.17	0.38	0.17	0.24	0.09
95% CI	0.46–0.74	0.41–0.74	0.49–0.77	0.41–0.74	0.32–0.68	0.09–0.24	0.30–0.46	0.03–0.30	–0.17–0.65	0.03–0.16

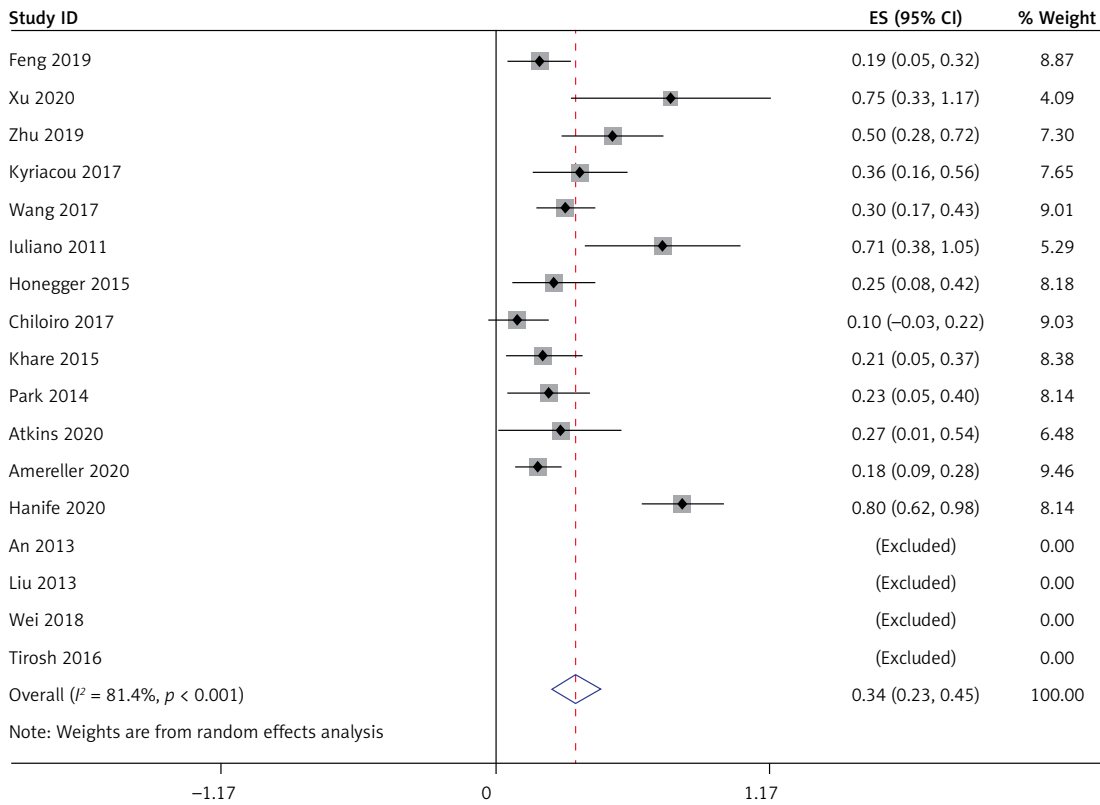


Figure 7. Surgical treatment

sis showed that the percentage of women in LYH patients was 78%, and LYH was associated with pregnancy in 15% of female patients. However, in recent years, cases have been reported in men and women of all ages. LYH is also associated with systemic autoimmune diseases: previous studies have shown an association in approximately 30–42% of LYH cases [24]. In our analysis, the figure was 24% and included Hashimoto’s thyroiditis, rheumatoid arthritis, Sjogren disease, systemic lupus erythematosus, Graves’ disease, psoriasis, and Guillain-Barre syndrome.

Magnetic resonance imaging is the imaging modality of first choice for saddle area lesions as it can clearly identify the morphology, size, and signal characteristics of the pituitary via coronal and sagittal views. MRI can accurately evaluate the growth pattern, invasion range, and the relationship between the lesion and the surrounding tissue. The signal changes of the neurohypophysis, the shape and position of the pituitary stalk, and the bone substance changes can also be clearly displayed [25]. LYH is often misdiagnosed as pituitary hyperplasia, pituitary tumor, or other diseases. The main manifestation of pituitary hyperplasia is diffuse enlargement of the pituitary gland: this returns the same uniform parenchymal signal and uniform enhancement as the normal pituitary gland on MRI. Compared with LYH, pituitary tumors have a distinct lesion boundary and

demonstrate delayed mild enhancement while the surrounding normal pituitary tissue shows obvious enhancement. The MRI manifestations of LYH in our analysis were pituitary contrast enhancement (63%), symmetrical pituitary enlargement (60%), thickening of the pituitary stalk (58%), sella mass or suprasellar extension (58%), loss of posterior pituitary hyperintensity (50%), chiasmal compression (38%), central pituitary necrosis (24%), cystic appearance (17%), cavernous sinus compression (17%), and dural tail sign (9%). Some authors regard the dural tail sign with retrodural involvement and enhancement as one of the signs of LYH [26].

Lymphocytic hypophysitis usually presents as a progressive process. Initially, inflammation and edema lead to enlargement of the pituitary gland and the patient presents with symptoms of mass effect. When the pituitary cells are destroyed and the glandular parenchyma is fibrotic, the pituitary atrophies, resulting in hypopituitarism. At present, the main treatment methods for LYH include steroid therapy, surgical therapy, immunosuppressive medical therapy, targeted therapy, and observation with hormone replacement therapy alone. Glucocorticoids can reduce inflammation, thereby reducing any space-occupying effects, and are available for diagnostic treatment in approximately 30% of patients [27], although long-term effects are not clear. There is no unified recommended

scheme for the treatment of LYH. For patients with severe or progressive exacerbation of acute or clinical symptoms, immunosuppressive agents based on glucocorticoids and surgery are the most commonly used active treatment for reducing masses. The commonly used regimen is high-dose prednisone or methylprednisolone shock therapy, followed by a dose decreasing stage of weeks and months. Wei's study showed that [10] the effective rate of glucocorticoid treatment was 54.5%. The main problems relating to steroid therapy are relapse after treatment and systemic complications caused by high dose or long-term use of glucocorticoids. Surgery can confirm the pathological diagnosis and can also remove pathological tissue to achieve decompression. Indications for surgical treatment include no response following steroid therapy, recurrence after remission, larger lesions, and compression symptoms such as visual loss and visual field defects. The main problems of surgical treatment are as follows [28]: (1) hypopituitarism will occur following surgery requiring lifelong hormone replacement therapy, and (2) the risk of surgical complications, such as cerebrospinal fluid rhinorrhea, infection, etc. Immunosuppression and targeted therapy are generally used for patients who have failed to respond to steroid therapy and surgery. Treatment with cyclophosphamide, methotrexate and rituximab has been reported [29]. However, due to the small number of cases, the specific drug regimen needs further study. Hormone replacement therapy is recommended when hormone deficiency or hypopituitarism occurs. Hormone replacement therapy is to supplement the corresponding target hormone of physiological dose, mainly glucocorticoid, thyroid hormone, sex hormone and desmopressin. Patients with pituitary hormone deficiency should receive long-term hormone replacement therapy, with more than 70% of patients requiring long-term hormonal substitution [5]. During this treatment, hormone levels should be monitored regularly, and drug doses should be adjusted as required. Patients with CDI should be treated with desmopressin or vasopressin supplementation. In addition, bromocriptine should be used in patients with hyperprolactinemia. It has been reported that spontaneous remission can occur in partial LYH cases: the pituitary mass can shrink spontaneously, anterior pituitary function can gradually recover in approximately 30% of patients, and, in a small number of cases, CDI can improve [30]. Therefore, for patients presenting with mild symptoms, watchful waiting may be a therapeutic option as recovery of hormonal function and improvements in imaging parameters may occur during the course of the disease [31]. Considering the limitations of steroid pulse therapy and surgical treatment, some scholars

advocate that observation and follow-up may be applied to a wider population. Unless symptoms are severe or disease progression occurs, observation and follow-up is the preferred treatment for LYH patients [4]. For patients with simple pituitary stalk thickening and CDI, it is found that the clinical outcomes of the observation group and the immunosuppressant treatment group are similar through follow-up. Therefore, such patients should be observed and closely followed up [10]. If MRI findings, endocrine function, or neurological symptoms indicate progression during follow-up, further intervention will be necessary. Our analysis showed that of 239 LYH patients, 36% were treated with steroids (mainly glucocorticoid pulse therapy), 34% were treated surgically, and 43% received clinical follow-up with observation or hormone replacement therapy.

In conclusion, lymphocytic hypophysitis is a relatively rare organ specific autoimmune disease characterized by extensive lymphocyte infiltration. It is easy to misdiagnose, and relapse after steroid treatment is common, as is pituitary dysfunction following surgery. The clinical manifestations include symptoms of mass effect and endocrine dysfunction. The characteristic MRI findings are an important basis for the clinical diagnosis of LYH. With continuous progress in diagnostic technology and the accumulation of clinical experience in diagnosis and treatment, the prognosis of LYH and quality of life for LYH patients will continue to improve. Because the research time and research background of the included literature are different, the normal reference range of hormones in different laboratories is different, the quality of some included literature is not high, and there is certain heterogeneity between different studies, the results of this meta-analysis should only be used as a reference for clinical work, and more large-sample, multicenter, high-quality and well-designed randomized controlled studies are required.

Acknowledgments

Jia-Sheng Ju and Tao Cui contributed equally to this study.

Conflict of interest

The authors declare no conflict of interest

References

1. Chiloiro S, Capoluongo ED, Tartaglione T, et al. The changing clinical spectrum of hypophysitis. *Trends Endocrinol Metab* 2019; 30: 590-602.
2. De Bellis A, Ruocco G, Battaglia M, et al. Immunological and clinical aspects of lymphocytic hypophysitis. *Clin Sci (Lond)* 2008; 114: 413-21.

3. Gutenberg A, Larsen J, Lupi I, Rohde V, Caturegli P. A radiologic score to distinguish autoimmune hypophysitis from nonsecreting pituitary adenoma preoperatively. *AJNR Am J Neuroradiol* 2009; 30: 1766-72.
4. Honegger J, Buchfelder M, Schlaffer S, et al. Treatment of primary hypophysitis in Germany. *J Clin Endocrinol Metab* 2015; 100: 3460-9.
5. Tirosh A, Hirsch D, Robenshtok E, et al. Variations in clinical and imaging findings by time of diagnosis in females with hypopituitarism attributed to lymphocytic hypophysitis. *Endocr Pract* 2016; 22: 447-53.
6. Zhu Q, Qian K, Jia G, et al. Clinical features, magnetic resonance imaging, and treatment experience of 20 patients with lymphocytic hypophysitis in a single center. *World Neurosurg* 2019; 127: e22-9.
7. Kyriacou A, Gnanalingham K, Kearney T. Lymphocytic hypophysitis: modern day management with limited role for surgery. *Pituitary* 2017; 20: 241-50.
8. Wang S, Wang L, Yao Y, et al. Primary lymphocytic hypophysitis: clinical characteristics and treatment of 50 cases in a single centre in China over 18 years. *Clin Endocrinol* 2017; 87: 177-84.
9. Iuliano SL, Laws ER. The diagnosis and management of lymphocytic hypophysitis. *Expert Rev Endocrinol Metab* 2011; 6: 777-8.
10. Qian W, Guoqing Y, Yijun L, et al. Clinical features and prognosis of 18 cases of primary lymphocytic hypophysitis. *Natl Med J China* 2018; 98: 102-8.
11. Jie F, Saichao Y, Dongming Y. Clinical analysis of 32 cases of lymphocytic hypophysitis. *The Journal of Practical Medicine* 2019; 35: 2065-9.
12. Xianglian A, Zhihong G, Mingcai Q. Early detection and management of lymphocytic hypophysitis. *Chin J Prey Contr Chron Dis* 2013; 21: 471-4.
13. Bing X, Xiangzhong H, Fan Z. Diagnosis and treatment of lymphocytic hypophysitis (report of four cases). *Chin J Stereotact Funct Neurosurg* 2020; 33:104-5.
14. Yanxia L, Qing Y, Xialian L, et al. Clinical analysis of 5 cases of lymphocytic hypophysitis. *Chin J Gen Pract* 2013; 12: 752-3.
15. Honegger J, Schlaffer S, Menzel C, et al. Diagnosis of primary hypophysitis in Germany. *J Clin Endocrinol Metab* 2015, 100: 3841-9.
16. Chiloiro S, Tartaglione T, Angelini F, et al. An overview of diagnosis of primary autoimmune hypophysitis in a prospective single-center experience. *Neuroendocrinology* 2017; 104: 280-90.
17. Khare S, Jagtap VS, Budya SR, et al. Primary (autoimmune) hypophysitis: a single centre experience. *Pituitary* 2015; 18: 16-22.
18. Park SM, Bae JC, Joung JY, et al. Clinical characteristics, management, and outcome of 22 cases of primary hypophysitis. *Endocrinol Metab* 2014; 29: 470-8.
19. Atkins P, Ur E. Primary and ipilimumab-induced hypophysitis: a single-center case series. *Endocr Res* 2020; 54: 246-53.
20. Amereller F, Küppers AM, Schilbach K, Schopohl J, Störmann S. Clinical characteristics of primary hypophysitis – a single-centre series of 60 cases. *Exp Clin Endocrinol Diabetes* 2020; 129: 234-40.
21. Oguz SH, Soylemezoglu F, Sendur SN, et al. Clinical characteristics, management, and treatment outcomes of primary hypophysitis: a monocentric cohort. *Horm Metab Res* 2020; 52: 220-7.
22. Imber BS, Lee HS, Kunwar S, Blevins LS, Aghi MK. Hypophysitis: a single-center case series. *Pituitary* 2015; 18: 630-41.
23. Angelousi A, Cohen C, Sosa S, et al. Clinical, endocrine and imaging characteristics of patients with primary hypophysitis. *Horm Metab Res* 2018; 50: 296-302.
24. Beressi N, Beressi JP, Cohen R, Modigliani E. Lymphocytic hypophysitis. A review of 145 cases. *Ann Med Interne (Paris)* 1999; 150: 327-41.
25. Ralot TK, Aggarwal J, Haniadka R, Gehlot K, Dongre N, Patil S. Lymphocytic hypophysitis mimicking pituitary macroadenoma. *J Assoc Physicians India* 2017; 65: 85-6.
26. Pekic S, Bogosav V, Peker S, et al. Lymphocytic hypophysitis? Successfully treated with stereotactic radiosurgery: case report and review of the literature. *J Neurol Surg A Cent Eur Neurosurg* 2018; 79: 77-85.
27. Korkmaz OP, Sahin S, Ozkaya HM, et al. Primary hypophysitis: experience of a single tertiary center. *Exp Clin Endocrinol Diabetes* 2021; 129: 14-21.
28. Karimnejad K, Sweeney J, Mantisdell JL. Cerebral vasospasm following transsphenoidal hypophysectomy in the treatment of lymphocytic hypophysitis. *J Craniofac Surg* 2016; 27: 988-91.
29. Xu C, Ricciuti A, Caturegli P, Keene CD, Kargi AY. Autoimmune lymphocytic hypophysitis in association with autoimmune eye disease and sequential treatment with infliximab and rituximab. *Pituitary* 2015; 18: 441-7.
30. Gilis-Januszewska A, Kluczyński Ł, Rogoziński D, Hubalewska-Dydejczyk A. Radiological and hormonal improvements in a 22-year-old patient with lymphocytic hypophysitis – the watchful waiting approach. *Endokrynol Pol* 2020; 71: 104-5.
31. Kluczyński Ł, Gilis-Januszewska A, Rogoziński D, Pantofliński J, Hubalewska-Dydejczyk A. Hypophysitis – new insights into diagnosis and treatment. *Endokrynol Pol* 2019; 70: 260-9.